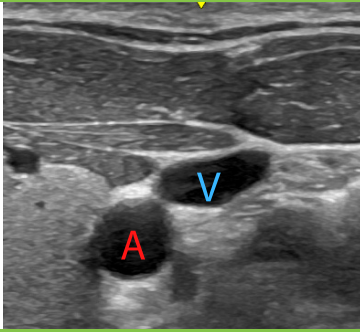
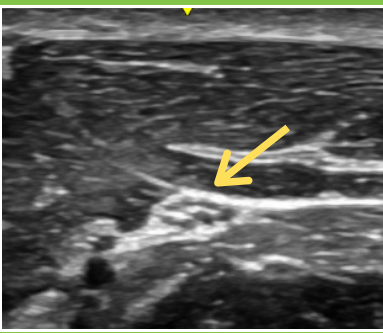
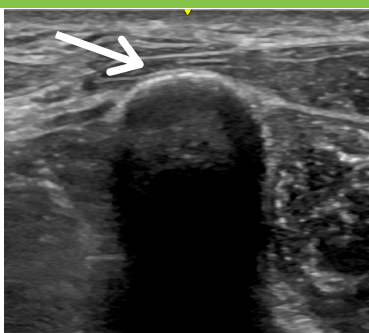
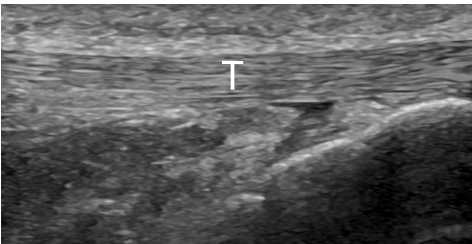
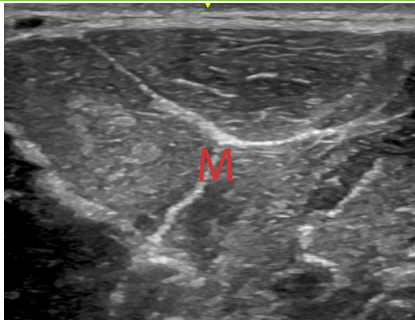


Structural Appearance

	<p>blood vessel</p>	<p>looks like: straw/tube artery = pulsatile vein = compressible/collapsible</p>
	<p>nerve</p>	<p>looks like: honeycomb cereal -fascicular pattern (black dot fascicles within the nerve) -often near artery and vein</p>
	<p>bone</p>	<p>-bright hyperechoic border with post acoustic shadowing</p>
	<p>tendon</p>	<p>-looks like: dry spaghetti -fibrillar pattern (collagen fibrils within the tendon)</p>
	<p>muscle</p>	<p>-looks like: steak -starry night -striations -surrounding connective tissue and fascia more hyperechoic</p>